



www.cnrs.fr



Assistance Publique  
Hôpitaux de Marseille

NATIONAL PRESS RELEASE | PARIS | 12 JANUARY 2016

## Is autism hiding in a fold of the brain?

Scientists at CNRS, Aix-Marseille Université and AP-HM have identified a cerebral marker specific to autism that can be detected by MRI and is present as from the age of two years. The abnormality thus detected consists in a less deep fold in Broca's area, a region of the brain specialized in language and communication, functions that are impaired in autistic patients. This discovery may assist in the earlier diagnosis and management of these patients. It has been made possible by the medical imaging processing skills of the Institut de Neurosciences de la Timone (CNRS/Aix-Marseille Université) and access to a homogeneous cohort of patients diagnosed at a very young age and all assessed using the same protocol at the Centre de Ressources Autisme PACA. The results of their collaboration are published on 12 January 2016 in *Biological Psychiatry: Cognitive Neurosciences and Neuroimaging*.

The autistic spectrum covers a range of neuro-developmental disorders (typical autism, Asperger's syndrome or pervasive developmental disorders not otherwise specified) which mainly affect social relationships and communication. These disorders are associated with abnormal development of the brain. Recent neuroimaging findings have notably suggested the existence of abnormal cortical folding (the formation of convolutions on the surface of the brain). However, standard neuro-anatomical measurement techniques had failed until now to demonstrate any markers specific to each of these disorders, and notably typical autism.

Scientists at the Institut de Neurosciences de la Timone (in Marseille, France) focused on a new geometric marker called the "sulcal pit". This is the deepest point of each sulcus in the cerebral cortex, from which points all the folds on the brain's surface develop. They are therefore put in place at a very early developmental stage, probably under genetic influences, which means they are indicators adapted to comparisons between different individuals.

Based on MRI findings, the scientists observed the sulcal pits of 102 young boys aged 2 to 10 years, who were placed in three groups (those with autistic disorder, pervasive developmental disorder not otherwise specified, and typically developing children). By comparing these three groups, they discovered that in Broca's area (a region known to be involved in language and communication), the maximum depth of a sulcus was less among autistic children when compared with the other two groups. Interestingly, this highly localized atrophy was correlated with the social communication performance of children in the autistic group: although it seems counterintuitive, among the autistic group, the deeper the sulcal pits, the more impaired were their skills in terms of language production.

This abnormality specific to autistic children may therefore constitute a biomarker for the disease that could enable their earlier diagnosis and management, as from the age of two years. Indeed, at present, autism

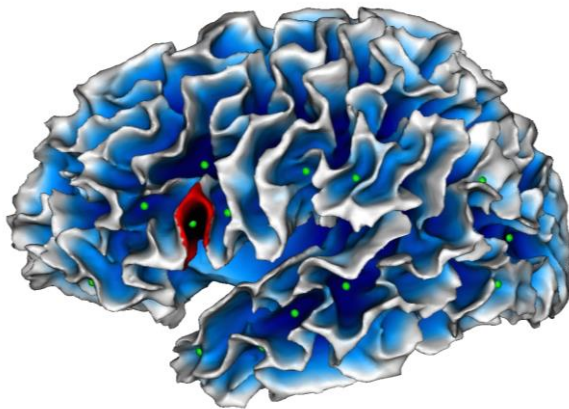


www.cnrs.fr



can only be diagnosed based on clinical signs, through the observation of children and interviews with their parents<sup>1</sup>.

This study has also enabled a discovery concerning brain development. While it was previously thought that cortical folding was complete at birth, the scientists observed that some folds (the most superficial) continued to deepen with age and in an identical manner in both autistic and other children. Biomedical research may therefore help to improve our understanding of the mechanisms of life.



**Mapping of cortical fold depths.**

In green: sulcal pits (the deepest point of each fold). In red: localization of the abnormality detected in autistic children (in Broca's area).

© SCALP team / INT

## Bibliography

**Localized misfolding within Broca's area as a distinctive feature of autistic disorder**, Lucile Brun, Guillaume Auzias, Marine Viellard, Nathalie Villeneuve, Nadine Girard, François Poinso, David Da Fonseca & Christine Deruelle. *Biological Psychiatry: Cognitive Neurosciences and Neuroimaging*, 12 January 2016. DOI: 10.1016/j.bpsc.2015.11.003

## Contacts

**CNRS Scientist** | Christine Deruelle | T +33 (0)4 91 32 40 36 | [christine.deruelle@univ-amu.fr](mailto:christine.deruelle@univ-amu.fr)  
**CNRS Press Office** | Véronique Etienne | T +33 (0)1 44 96 51 37 | [veronique.etienne@cnrs-dir.fr](mailto:veronique.etienne@cnrs-dir.fr)

<sup>1</sup> This is generally only achieved at the age of 4½ years in France.